

Comparison of Three-Dimensional Imaging to Transesophageal Echocardiography for Preoperative Evaluation in Mitral Valve Prolapse

Silvana Müller, MD^a, Ludwig Müller, MD^b, Günther Laufer, MD^b, Hannes Alber, MD^a, Wolfgang Dichtl, MD^a, Matthias Frick, MD^a, Otmar Pachinger, MD^a, and Thomas Bartel, MD^{a,*}

Transesophageal echocardiography (TEE) is not optimally suited for recognizing which valve segments are involved in type II mitral valve dysfunction. This study was conducted to compare the diagnostic value of TEE and 3-dimensional image reconstruction (3DIR) in the assessment of Carpentier type II mitral valve lesions. In 74 patients (mean age 59 ± 13 years) with mitral regurgitation due to type II valve dysfunction, TEE and 3DIR were performed and analyzed by 2 experts before surgical repair. Leaflet scallops and commissures were displayed in short-axis en face and long-axis views. Echocardiographic results were surgically validated. Sensitivity, specificity, positive predictive value, negative predictive value, and accuracy were calculated, broken down by valve segments and Barlow's disease. Interobserver variability was also determined. Compared with TEE, 3DIR was superior with respect to sensitivity, positive and negative predictive values, and accuracy, although not always significantly ($p < 0.05$). Specificity was higher for P2 lesions. The clearest advantage of 3DIR over TEE was higher sensitivity in commissural and bileaflet defects ($p < 0.05$). Interobserver agreement on 3DIR was stronger than on TEE results (κ values 0.52 vs 0.82, $p < 0.0001$). There were 16 disagreements (23%) on TEE but only 5 (7%) on 3DIR readings. In conclusion, the more complex the lesion, the more valuable 3DIR is compared with TEE. Before repair, 3DIR is beneficial for the evaluation and classification of the specific pathology in type II mitral valve dysfunction. © 2006 Elsevier Inc. All rights reserved. (Am J Cardiol 2006;98:243–248)

To overcome the limitations inherent in transesophageal echocardiography (TEE),^{1,2} 3-dimensional image reconstruction (3DIR) was introduced. This method permits perioperative atrial en face imaging and serial longitudinal viewing of the exact site of mitral valve regurgitation and its underlying mechanism(s).^{3–7} Nevertheless, it is not yet clear under which specific circumstances this advanced diagnostic method is capable of improving diagnostic certainty and how time consuming 3DIR actually is. Hypothesizing that 3DIR is superior to conventional TEE, we compared the time required for each examination as well as the sensitivity, specificity, and positive and negative predictive values of both methods broken down by mitral valve scallops and commissures. For this purpose, 3DIR and TEE readings were performed in patients with type II mitral valve dysfunction before surgical repair.^{8–10}

Methods

Study population: From 2001 to 2004, 74 consecutive patients with mitral regurgitation due to Carpentier type II

mitral valve dysfunction⁸ were prospectively studied (Table 1) between 1 week and 2 months before mitral valve surgery. These patients were then scheduled for surgical treatment in accordance with the guidelines for the management of patients with valvular heart disease (American College of Cardiology/American Heart Association Task Force on Practice Guidelines¹⁰).

Nomenclature and classification: Carpentier's classification of mitral valve regurgitation is based on the mobility of the valvular tissue and the respective dysfunction. Type II dysfunction is defined as a prolapsing mitral valve segment, flail leaflet, Barlow's disease, or a combination of these.⁸ In Barlow's disease, also known as billowing mitral leaflet syndrome, the leaflets bulge into the left atrium (LA) due to redundant leaflet tissue and elongated chordae tendineae. Typically, the free edge of the leaflet is on the ventricular aspect, ahead of the mitral annular plane. A prolapse is identified when a mitral valve segment protrudes into the LA and the free edge turns down toward the left ventricle and remains beyond the annular plane during systole. In contrast, a flail leaflet fully protrudes into the LA and the leaflet tip turns upward toward the LA due to ruptured chordae tendineae.¹¹

Carpentier also proposed what became the standard surgical nomenclature for the mitral valve. According to Carpentier,¹² the posterior mitral valve leaflet (PML) is

^aCardiology Division, Department of Internal Medicine and ^bDepartment of Cardiac Surgery, University of Innsbruck, Innsbruck, Austria. Manuscript received October 4, 2005; revised manuscript received and accepted January 19, 2006.

* Corresponding author: Tel: 43512-504-81992; fax: 43512-504-23379.

E-mail address: thomas.bartel@uibk.ac.at (T. Bartel).

Table 1
Patient characteristics (n = 74)

Women	23 (31%)
Men	51 (69%)
Age (yrs)	59 ± 13* (range 24–76)
Atrial fibrillation	11 (15%)
Etiology	
Fibroelastic deficiency	52 (70%)
Barlow's disease	4 (5%)
Rheumatic valve disease	11 (15%)
Undetermined	7 (10%)

* Is Mean ± SD.

Table 2
Transesophageal echocardiography of mitral valve scallops

Cross Sections	Scallops
Transgastric basal short axis (0°)	C1–C2
Mid-esophageal 5-Chamber view (0°)	A1/A2–P2
4-Chamber view (0°)	A2/A3–P2/P3
4-Chamber view (40°)	A2/A3–P1
Commissural view (60°)	P3–A2–P1 (LAA visible)
2-Chamber view (90°)	P3–A1
Long-axis view (120–150°)	P2–A2

Systematic assessment of 8 mitral valve segments in accordance with the Carpentier nomenclature and the Guidelines of the American Society of Echocardiography in patients with mitral valve prolapse, flail, and endocarditis.^{13,14}

LAA = left atrial appendage.

divided into 3 scallops, P1, P2, and P3, which are anatomically evident. Correspondingly, the anterior mitral valve leaflet (AML) is divided into 3 scallops, A1, A2, and A3. These are not anatomically evident, but face the corresponding scallops of the PML. In addition, the anterolateral commissure is named C1 and the posteromedial commissure C2. For the present study, we use this nomenclature and the Guidelines of the American Society of Echocardiography in patients with mitral valve prolapse, flail, and endocarditis.¹³

Echocardiographic examination: TEE was performed with a 7-MHz transesophageal probe and a commercial ultrasonographic unit (Sequoia C256, Acuson-Siemens Inc., Mountain View, California). The mitral valve was systematically imaged using distinct cross-sectional views to identify all valve segments and to assure precise localization of the pathologic changes (Table 2). Each examination started with the transgastric view. The commissures are best seen in the basal short axis. After probe withdrawal, a mid-esophageal 5-chamber view displays the segments A1, A2, and P2 at 0° and the segments A2, A3, and P1 at 40°. At 60°, the left atrial appendage borders on the P1 segment and A2 is displayed between the P3 and P1 segments. P3 and A1 segments are seen after further rotation at 90° as are the P2 and A2 segments at 120° to 150°. After completion of these standard TEE diagnostics, a 3-dimensional Windows NT work station (TomTec Imaging Systems Corp.,

Munich, Germany) connected to the ultrasonographic unit was used to acquire 3-dimensional data sets. For data acquisition, the probe was rotated from 0° to 180° at 2° intervals with electrocardiographic and respiratory gating. To fully analyze the pathologic changes of the mitral valve, each scallop and the commissures were displayed in short-axis en face views as well as in long-axis views using offline 3DIR.

The saddle shape of the mitral valve annulus makes visualization of leaflets and the commissures in 1 single short-axis view challenging. To facilitate spatial orientation, the following cut planes were used to create the en face images: (1) orthogonal 4-chamber view, including the right ventricle and the aorta and (2) 2-chamber view, including the left atrial appendage and the aorta. Nevertheless, short-axis en face views are of paramount importance. They are capable of displaying all segments, including the commissures in 1 image. The left atrial appendage and the aorta serve as landmarks to facilitate orientation. C1 and P1 segments are displayed next to the left atrial appendage and the A2 segment next to the aorta. The coaptation line between AML and PML is strongly curved. Therefore, the concave side is formed by the larger AML and the convex 1 by the smaller PML. By tilting the short-axis image slightly, AML or PML and 1 of the commissures were fully visualized.¹⁴ In addition, serial longitudinal cuts were placed through the corresponding lateral, middle, and medial scallops of the leaflets to visualize a pair of scallops, 1 scallop belonging to the AML and the other to the PML. In short-axis en face views, prolapse and flail are depicted and can be clearly assigned to distinct segments. Prolapsing segments typically arch toward the viewer during systole, whereas flail segments show uncontrolled movement into the LA.

In all patients, the duration of this entire process of image acquisition and 3DIR, including manipulation of image planes and optimization of image presentation for interpretation, was measured and compared with the duration of the examination of the mitral valve by TEE. Both examinations were analyzed by 2 observers. The first observer was the examiner and the second viewed the videotape of the TEE examination and performed 3DIR from the stored data sets. Both observers met American Society of Echocardiography Level III guidelines¹⁵ and were mutually blinded and blinded to the surgical results. The second examiner had an experience of about 11 years interpreting 3-dimensional images. To assess the differences between TEE findings, the grading system published by Chan et al¹⁶ was used.

Statistical analyses: Parametric data are expressed as mean ± SD and as a percentage for categorical variables. The paired 2-tailed Student's *t* test was used to analyze differences between the duration needed for 3DIR compared with the time required for TEE. Sensitivity, specific-

Table 3
Surgical findings in Carpentier type II lesions

Segment	All (%)	Isolated Lesions	Combined Lesions	Combinations (n)
P1	2 (3%)	0	2	P1-A1-C1 (1) P1-P2-P3 (1)
P2	54 (73%)	43	11	P2-P3 (7) P2-A2 (1) P2-P3-A3 (1) P2-C2 (1)
P3	14 (19%)	1	13	P3-C1 (2) P3-A3 (1) P3-A2-A3-C2 (1)
A1	2 (3%)	0	2	A1-A2 (1)
A2	11 (15%)	4	7	A2-A3-C2 (1) A2-A3 (2) A2-A3-BA (1)
A3	7 (10%)	0	7	see P2, P3, A2
C1	5 (7%)	2	3	see P1, P3
C2	3 (4%)	0	3	see P2, P3, A2
BA	4 (6%)	3	1	see A2

Isolated lesions are assigned to the respective scallop or Barlow's disease. Combined lesions are listed once (under the first involved segment in table order).

ity, positive predictive value, and negative predictive value of TEE and 3DIR were determined as follows:

$$\text{Sensitivity} = \frac{\text{True positives}}{\text{True positives} + \text{False negatives}} \cdot 100\%$$

$$\text{Specificity} = \frac{\text{True negatives}}{\text{True negatives} + \text{False positives}} \cdot 100\%$$

Positive predictive value

$$= \frac{\text{True positives}}{\text{True positives} + \text{False positives}} \cdot 100\%$$

Negative predictive value

$$= \frac{\text{True negatives}}{\text{True negatives} + \text{False negatives}} \cdot 100\%$$

In addition, the overall diagnostic accuracy of TEE and 3DIR with respect to the identification of diseased valve segments was calculated as the sum of true positives and true negatives divided by the sum of total positives and total negatives. To compare the sensitivity of TEE and 3DIR with respect to the involvement of each scallop and the commissures as well as respective combinations, McNemar's test was used. The interobserver variability of both methods was assessed by κ analysis. A Cohen κ coefficient of 1.0 indicates complete agreement, whereas a value of 0.0 indicates a chance agreement. The observers reached a consensus in cases of disagreement before the result was compared with the surgical findings. All statistical analyses were completed with SPSS for Windows (release 10.0.1, SPSS Inc., Chicago, Illinois). Statistical significance was defined as a $p < 0.05$.

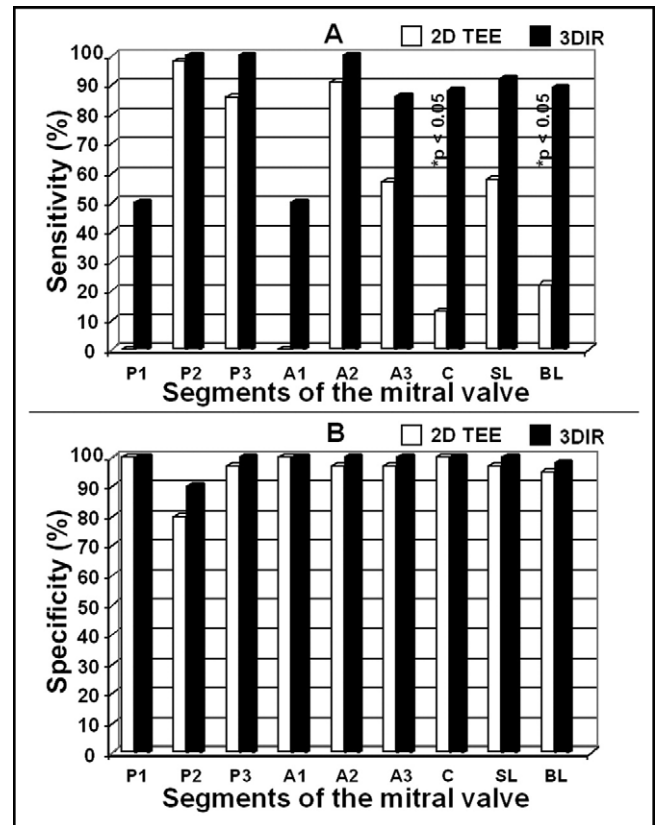


Figure 1. Comparative evaluation of TEE and 3-dimensional echocardiography in mitral valve prolapse/flail. (A) Sensitivity and (B) specificity. White bars, 2-dimensional TEE; black bars, 3DIR; *McNemar's test revealed significant differences in sensitivity. BL = bileaflet involvement or combined lesion including the commissures; C = commissures; SL = single leaflet but multiscallop involvement.

Results

Population characteristics: Valve reconstruction was preferred whenever possible and carried out in 70 patients (95%), whereas 4 patients (5%) underwent mitral valve replacement. Using an anterolateral mini-thoracotomy and port access, the procedure was completed by a minimally invasive video-assisted approach in 13 patients (18%). Intraoperatively (Table 3), an isolated prolapse or single flail scallop was found in 50 patients (68%) (Figure 1). In 20 patients (27%) without Barlow's disease, >1 scallop was involved (Figure 2). The scallop most frequently involved was P2, followed by P3, A2, and A3. Except for P2 lesions, all scallops were involved in multiscallop disease in $\geq 50\%$ of the cases. Prolapse of 1 of the commissures was evident in 7 patients (10%). In 49 subjects (69%), a flail leaflet was found.

Comparative evaluation of TEE and 3DIR: Sensitivity, specificity, positive and negative predictive values, and overall diagnostic accuracy were separately calculated for TEE and 3DIR. These results were broken down by the involved scallop(s); combined lesions were included (Figure 1 and Table 4). In comparison, superiority of 3DIR was not consistently statistically significant (because of the low fre-

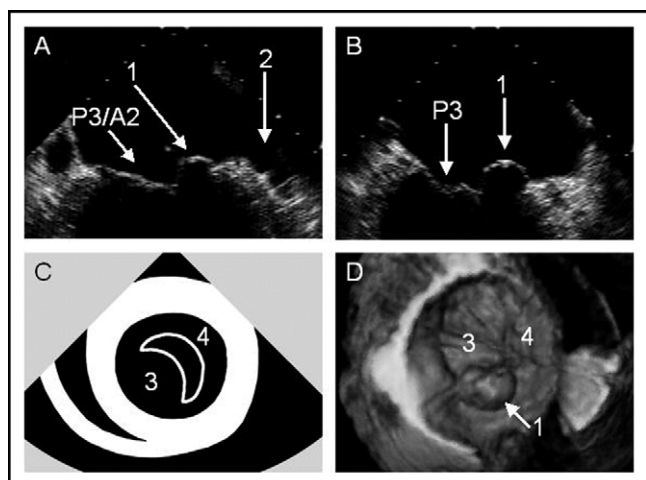


Figure 2. TEE and 3-dimensional echocardiography in prolapse of C1. (A) Mid-esophageal commissural view (60°) suggests the P1 scallop to be effected; (B) mid-esophageal 2-chamber view (90°) (2-dimensional imaging does not distinguish whether A1, C1, or P1 segments are involved); (C) transgastric basal short-axis view (0°) normally showing the commissures¹⁹ was not diagnostic in this patient; (D) 3-dimensional "all-in-1" imaging reveals sole C1 involvement. 1 indicates prolapse of C1; 2, left atrial appendage; 3, anterior mitral leaflet; 4, posterior mitral leaflet.

Table 4

Comparative evaluation of transesophageal echocardiography and three-dimensional image reconstruction (%)

Segment	PPV		NPV		ODA	
	2D TEE	3DIR	2D TEE	3DIR	2D TEE	3DIR
P1	0	100	97	99	97	99
P2	93	96	94	100	93	97
P3	86	100	97	100	95	100
A1	0	100	97	99	97	99
A2	83	100	98	100	96	100
A3	67	100	96	99	93	99
C	13	88	90	99	91	99
SL	78	100	92	98	91	99
BL	40	89	90	98	86	97

BL = bileaflet involvement or combined involvement including 1 or both commissures; C = commissure(s); NPV = negative predictive value; ODA = overall diagnostic accuracy; PPV = positive predictive value; SL = single leaflet but multisegment involvement.

quency of some lesions). Comparative evaluation revealed, however, that the sensitivity, positive and negative predictive values, and overall diagnostic accuracy of 3DIR were higher than with TEE. This was true for all valve segments. The sensitivities of TEE and 3DIR were significantly different for combined lesions involving anterior plus posterior scallops or ≥ 1 of the commissures (Figures 2 and 3). It is true that 3DIR was only slightly more sensitive, but 3DIR proved to be clearly more specific than TEE with regard to isolated P2 lesions (Figure 4). The P2 segment was by far the most frequently diseased segment. For the remaining segments, the specificity of 3DIR was not or only slightly superior to TEE. The negative predictive value of 3DIR was demonstrated to be higher than that of TEE, especially with

respect to commissural and combined lesions and to a lesser extent also to P2 lesions (Table 4). In parallel, the overall diagnostic accuracy of 3DIR was primarily better regarding combined and commissural lesions, but also for lesions of the A3 and P2 scallops. Both diagnostic approaches reliably detected all cases of Barlow's disease and ruled it out in the remaining 70 patients. The time needed for 3DIR was marginally longer than that required to complete TEE (14.6 ± 1.5 minutes [range 12.1 to 18.1] vs 10.1 ± 2.9 minutes [range 5.0 to 15.6], $p < 0.0001$). The additional time required for 3DIR was 4.5 ± 2.1 minutes. Using the classification published by Chan et al,¹⁶ 3-dimensional studies were graded A in 17 cases (23%), B in 54 cases (73%), and C in 3 cases (4%). All studies graded A revealed commissural lesions or bileaflet involvement.

Interobserver agreement: Interobserver agreement was moderate for TEE diagnoses but strong for 3DIR findings (κ values 0.52 vs 0.82, $p < 0.0001$). There were 16 disagreements (22%) between the observers on TEE interpretation. In 5 of these cases, 1 of the commissures was involved. In 9 other patients, multisegmental involvement was evident. With respect to 3DIR diagnoses, the reviewers disagreed in only 5 cases (7%). One patient had a lesion affecting 4 scallops, the other 4 subjects had combined lesions involving 3 scallops.

Discussion

The recently introduced technique of targeted 3DIR² can accurately classify various Carpentier type II⁸ mitral valve lesions, including commissural and multisegmental lesions. Classification is more reliable than by conventional TEE, the established approach for about a decade.^{14,17-19} Because mitral valve repair is superior to valve replacement,²⁰⁻²² it is crucial to be able to detect those lesions known to be independent predictors for unsuccessful repair, such as extensive leaflet disease.²³ This becomes even more important in light of the trend toward a minimally invasive surgical approach, which mandates highly detailed information before repair. Although widely used,^{17,18} TEE was found to be a less than optimal preoperative diagnostic tool. There are several reasons: (1) to understand the complex anatomy and specific pathology, mental integration of a limited number of 2-dimensional images is mandatory¹; (2) sensitivity and specificity of conventional TEE are prone to decrease if > 1 scallop or the commissures are involved²; and (3) TEE images of a diseased mitral valve are not self-explanatory, but must be explained to staff members who are not completely familiar with TEE diagnostics of the mitral valve, because TEE imaging has become such a crucial element in the joint discussion between cardiologists and surgeons.

The present results add significantly to previously reported findings indicating that perioperative 3DIR can clearly facilitate optimal valve repair.^{7,24} Involvement of the P1, A1, and A3 scallops is rare or extremely rare^{14,23} and only found in combined lesions. For these segments, 3DIR

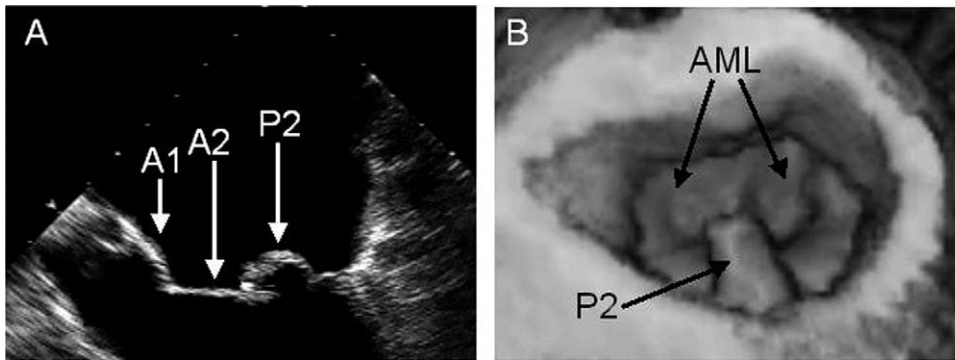


Figure 3. Both echocardiographic methods clearly depict a lesion of the P2 scallop. (A) Mid-esophageal 5-chamber view (0°) and (B) 3-dimensional view from the LA.

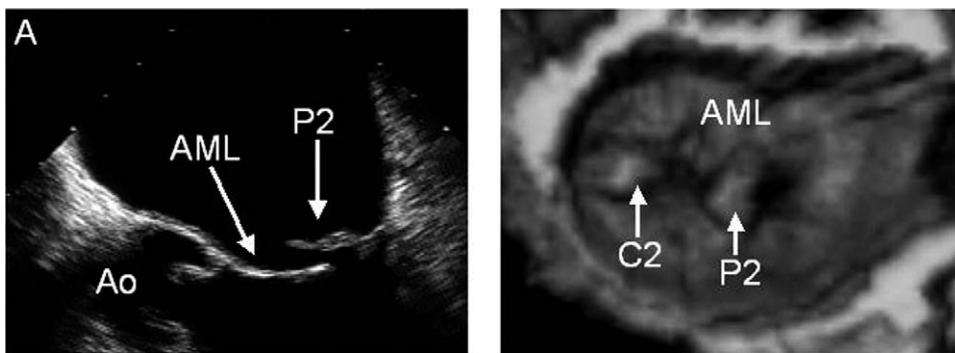


Figure 4. Flail of the P2 scallop is demonstrated by both echocardiographic approaches, but C2 prolapse was only detectable by 3-dimensional echocardiography. (A) Mid-esophageal 5-chamber view (0°) and (B) 3DIR demonstrates involvement of P2 and C2. Ao = aorta; C2 = posteromedial commissure.

is possibly more sensitive and has a higher positive predictive value than TEE, as was clearly demonstrated for bileaflet involvement and commissural lesions. In parallel, the accuracy of TEE decreases in commissural and combined lesions, a phenomenon much less pronounced with 3DIR. The more complex the mitral valve lesions are, the more beneficial 3DIR is in comparison with TEE for the accurate depiction of the underlying pathology before repair. The more common a lesion is, the more specific 3DIR is in comparison with TEE. The recommendation to extend each echocardiographic evaluation of type II mitral valve dysfunction to 3DIR is obviously justified, because in 96% of all cases with type II mitral valve dysfunction, 3DIR provided either new findings not detected by TEE (grade A¹⁶) or a unique anatomic perspective, a fact especially useful for cardiac surgeons (grade B¹⁶). As previously reported,¹⁴ 3DIR may not always accurately detect the lesion if >2 scallops are involved in a bileaflet defect.

The latest TomTec technology and direct control of a standard ultrasound unit by the Windows NT work station make the examination quite time efficient. Now, 3DIR studies are only slightly more time consuming than complete TEE examinations, which can be easily extended by 3-dimensional data acquisition. If standard 3-dimensional views are reconstructed, interobserver reproducibility is high. Tar-

geted and standardized 3DIR, as recently proposed,² are prerequisites for reproducing these results.

The lack of significant sensitivity differences between TEE and 3DIR is caused by the small number of some lesions. Therefore, some data must be considered observational. Nevertheless, a certain superiority of 3DIR with respect to rare single-scallop lesions can be extrapolated from the cases in this study. Because Barlow's disease was rarely seen in this population, the diagnostic value of 3DIR was difficult to compare with that of TEE, but appeared to be high with either technique. Although the majority of patients presented with fibroelastic deficiency, the population was heterogeneous due to different underlying diseases. The study was also limited by having only 2 observers view and evaluate TEE and 3DIR.

Acknowledgment: We thank Navin Nanda, MD, for his insightful review and expert comments.

1. Sutaria N, Northridge D, Masani N, Pandian N. Three-dimensional echocardiography for the assessment of mitral valve disease. *Heart* 2000;84 (suppl 2):117-10.
2. Macnab A, Jenkins NP, Ewington I, Bridgewater BJ, Hooper TL, Greenhalgh DL, Patrick MR, Ray SG. A method for the morphological analysis of the regurgitant mitral valve using three dimensional echocardiography. *Heart* 2004;90:771-776.

3. Pandian NG, Roelandt J, Nanda NC, Sugeng L, Cao QL, Azevedo J, Schwartz SL, Vannan MA, Ludomirski A, Marx G. Dynamic three-dimensional echocardiography. Methods and clinical potential. *Echocardiography* 1994;11:237–259.
4. Salustri A, Becker AE, van Herwerden L, Vletter WB, Ten Cate FJ, Roelandt JR. Three-dimensional echocardiography of normal and pathologic mitral valve: a comparison with two-dimensional transesophageal echocardiography. *J Am Coll Cardiol* 1996;27:1502–1510.
5. Hozumi T, Yoshikawa J, Yoshida K, Akasaka T, Takagi T, Yamamuro A. Assessment of flail leaflets by dynamic three-dimensional echocardiographic imaging. *Am J Cardiol* 1997;79:233–235.
6. Cheng TO, Xie MX, Wang XF, Li ZA, Hu G. Evaluation of mitral valve prolapse by four-dimensional echocardiography. *Am Heart J* 1997;133:120–129.
7. Chauvel C, Bogino E, Clerc P, Fernandez G, Vernhet JC, Becat A, Dehant P. Usefulness of three-dimensional echocardiography for the evaluation of mitral valve prolapse: an intraoperative study. *J Heart Valve Dis* 2000;9:341–349.
8. Carpentier A, Chauvaud S, Fabiani JN, Deloche A, Relland J, Lessana A, D'Allaines C, Blouneau P, Piwnica A, Dubost C. Reconstructive surgery of mitral valve incompetence: a ten-year appraisal. *J Thorac Cardiovasc Surg* 1980;79:338–348.
9. Kay GL, Aoki A, Zubiate P, Prejean CA Jr, Ruggio JM, Kay JH. Probability of valve repair for pure mitral regurgitation. *J Thorac Cardiovasc Surg* 1994;108:871–879.
10. Bonow RO, Carabello B, de Leon AC, Edmunds LH Jr, Fedderly BJ, Freed MD, Gaasch WH, McKay CR, Nishimura RA, O'Gara PT, et al. Guidelines for the management of patients with valvular heart disease: executive summary. *Circulation* 1998;98:1949–1984.
11. Pellerin D, Brecker S, Veyrat C. Degenerative mitral valve disease with emphasis on mitral valve prolapse. *Heart* 2002;88(suppl IV):iv20–28.
12. Carpentier AF, Lessana A, Relland J, Belli E, Mihaileanu S, Berrebi AJ, Palsky E, Loulmet DF. The “physio-ring”: an advanced concept in mitral valve annuloplasty. *Ann Thorac Surg* 1995;60:1177–1186.
13. Agricola E, Oppizzi M, De Bonis M, Maisano F, Toracca L, Bove T, Alfieri O. American Society of Echocardiography. Multiplane transesophageal echocardiography performed according to the Guidelines of the American Society of Echocardiography in patients with mitral valve prolapse, flail, and endocarditis: diagnostic accuracy in the identification of mitral regurgitant defects by correlation with surgical findings. *J Am Soc Echocardiogr* 2003;16:61–66.
14. Ahmed S, Nanda NC, Miller AP, Nekkanti R, Yousif AM, Pacifico AD, Kirklin JK, McGiffin DC. Usefulness of transesophageal three-dimensional echocardiography in the identification of individual segment/scallop prolapse of the mitral valve. *Echocardiography* 2003;20:203–209.
15. ACC/AHA clinical competence statement on echocardiography. A report of the American College of Cardiology/American Heart Association/American College of Physicians - American Society of Internal Medicine - Task Force on Clinical Competence. *J Am Coll Cardiol* 2003;41:687–708.
16. Chan KL, Liu X, Ascah KJ, Beauchesne LM, Burwash IG. Comparison of real-time 3-dimensional echocardiography with conventional 2-dimensional echocardiography in the assessment of structural heart disease. *J Am Soc Echocardiography* 2004;17:976–980.
17. Steward WJ, Griffin B, Thomas JD. Multiplane transesophageal echocardiographic evaluation of mitral valve disease. *Am J Card Imaging* 1995;9:121–128.
18. Caldarera I, Van Herwerden LA, Taams MA, Bos E, Roelandt JR. Multiplane transesophageal echocardiography and morphology of regurgitant mitral valves in surgical repair. *Eur Heart J* 1995;16:999–1006.
19. Lambert AS, Miller JP, Merrick SH, Schiller NB, Foster E, Muhiudeen-Russell I, Cahalan MK. Improved evaluation of the location and mechanism of mitral valve regurgitation with a systematic transesophageal echocardiographic examination. *Anesth Analg* 1999;88:1205–1212.
20. Carabello BA. The mitral valve apparatus: is there still room to doubt the importance of its preservation? *J Heart Valve Dis* 1993;2:250–252.
21. Hansen DE, Sarris GE, Niczyporuk MA, Derby GC, Cahill PD, Miller DC. Physiologic role of the mitral apparatus in left ventricular regional mechanics, contraction synergy, and global systolic performance. *J Thorac Cardiovasc Surg* 1989;97:521–533.
22. Carabello BA, Crawford FA. Valvular heart disease. *N Engl J Med* 1997;337:32–41.
23. Omran AS, Woo A, David TE, Feindel CM, Rakowski H, Siu SC. Intraoperative transesophageal echocardiography accurately predicts mitral valve anatomy and suitability for repair. *J Am Soc Echocardiogr* 2002;15:950–957.
24. De Castro S, Salandin V, Cartoni D, Valfre C, Salvador L, Magni G, Adoriso R, Papetti F, Beni S, Fedele F, Pandian NG. Qualitative and quantitative evaluation of mitral valve morphology by intraoperative volume-rendered three-dimensional echocardiography. *J Heart Valve Dis* 2002;11:173–180.